

## Clubbing An Initial Pointer Towards Diagnosis of Malignancy

Syed Mohsin Ishaq<sup>1</sup>, Apoorv Singhal<sup>2</sup>, Praveen Raman Mishra<sup>3</sup>,  
VPS Puniya<sup>4</sup>, Shan Khan<sup>5</sup>, Mehak Lamba<sup>6</sup>

### Author's Affiliation:

<sup>1</sup>Senior Resident <sup>2,3</sup>Junior Resident  
<sup>4</sup>Professor <sup>5</sup>Resident <sup>6</sup>Assistant  
Professor, Department of Internal  
Medicine, Sharda University,  
Knowledge Park III, Greater Noida,  
Uttar Pradesh 201310, India.

### Corresponding Author:

**Syed Mohsin Ishaq**, Senior  
Resident, Department of Internal  
Medicine, Sharda University,  
Knowledge Park III, Greater Noida,  
Uttar Pradesh 201310, India.

E-mail: [syedmhsn6@gmail.com](mailto:syedmhsn6@gmail.com)

Received on 08.07.2019,

Accepted on 23.10.2019

### Abstract

Clubbing is one of the ancient signs in clinical medicine since the time of Hippocrates. Its pathogenesis is said to be associated with platelet derived growth factor and vascular endothelial growth factor but exactly mechanism behind this is still unknown. We present a case of 55-years-old male admitted with complaints of fever, cough, pain and swelling of fingers. On examination he had Grade 4 clubbing and radiography revealed left upper lobe opacity with malignant features and subsequently bronchoscopy confirmed the diagnosis of squamous cell carcinoma.

**Keywords:** Clubbing, squamous cell carcinoma, HOA

How to cite this article:

Syed Mohsin Ishaq, Apoorv Singhal, Praveen Raman Mishra, et al. Clubbing An Initial Pointer Towards Diagnosis of Malignancy. Indian J Emerg Med. 2019;5(4):255-257

### Introduction

The clubbed fingers were firstly described by Hippocrates nearly 2500 years ago in a person with empyema condition. Hence are also known as watch-glass nails, drumstick fingers, and Hippocratic fingers/nail.

1. This state describes it as Hippocratic finger and is considered to be the oldest sign under clinical medicine.
2. Clubbed fingers were not only restricted to the empyema; later on, the clinical conditions found associated were bronchiectasis, lung cancer, liver cirrhosis, cyanotic congenital heart disease, etc.

3. Clinically, clubbing is classified into 5 stages.
4. Grade 1 oscillation and softening of the nail bed. Grade 2 modification in the angle between the nail bed and the proximal nail fold (usually an increase in the normal 160°). Grade 3 accentuated convexity of the nail. Grade 4 clubbed look of the fingertip. Grade 5 formation of a shiny or glossy appearance in nail and adjacent skin with longitudinal striations.

### Case Report

A 55-year-old male had shown pain and swelling of fingers, elbow joints for the last eight months.

He also referred to changes in the shape of his fingernails during this period.

### Patient history

Intermittent, cough, low-grade fever and significant weight loss of 5–7 kg over the last six months. The

patient was a heavy smoker for the past 50 years and a farmer by occupation. The patient had shown Grade IV digital clubbing, and shammroth sign was positive (Fig. 1.a,b,c). There was localized crepitation in the left apical zone. Bilateral distal interphalangeal joints were swollen and tender.

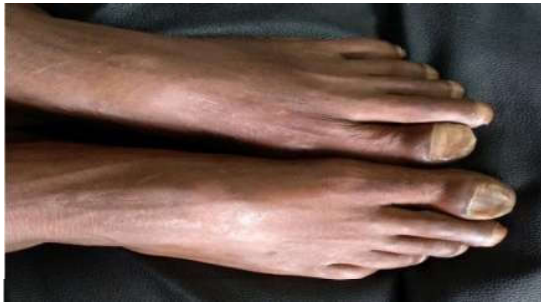

Fig. 1a:

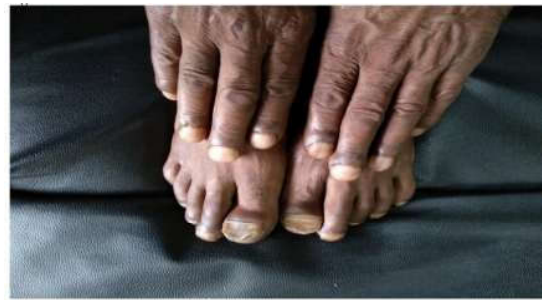

Fig. 1b:

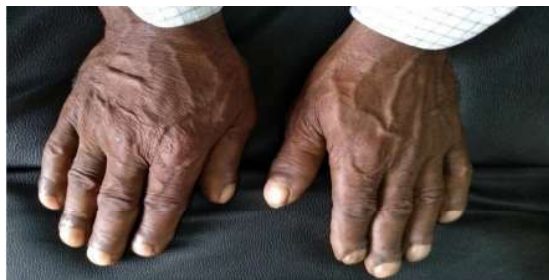

Fig. 1c:

His hemogram, kidney function test (KFT), liver function test (LFT), ECG, lipid profile and urine examination were within normal limits. ESR was raised to the order of 90 mm/hr. His Rheumatoid factor (RF) and anti-CCP anti-body were negative.

X-ray of the hands showed distal thickening of the fingers (Fig. 2). A solitary lesion in the upper zone of the left lung was detected in chest X-ray, and CT scan of the thorax showed a soft tissue mass (Fig. 3).

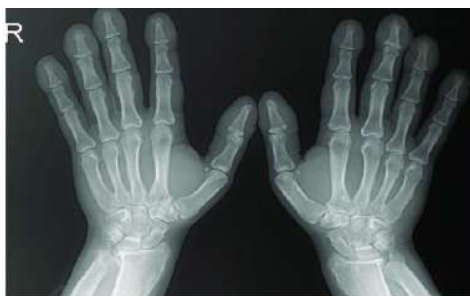

Fig. 2:

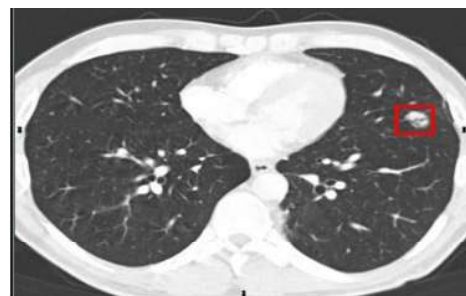


Fig. 3:

*Thorax X-ray:* Opacification in the left upper apical zone, with neoplastic characteristics. CT guided FNAC depicted clumps of malignant epithelial cells having squamous differentiation, indicative of squamous cell carcinoma.

*Bronchoscopy:* Absence of endobronchial lesions.

For neoplastic cells, brushing, bronchial washing and transbronchial biopsy in the right lower lobe were negative.

The procedure was repeated twice, with no definitive diagnosis. Focusing on the patient's clinical and radiological characteristics, videothorascopy (with a biopsy for freezing) was adopted that showed a polymitotic pathology.

The patient was diagnosed with hypertrophic pulmonary osteoarthropathy (HOA) which is secondary to squamous cell carcinoma of the lung, denoting as arthritis. He was treated with NSAID for pain relief and referred to the oncology department for further management.

### Discussion

HOA is manifested as painful, swollen joints, digital clubbing and periostitis. Pulmonary malignancies, both primary and metastatic accounts for almost 80% of cases of secondary HOA.

The pathogenic hypothesis says that there from pulmonary to the systemic circulation, there is shunting of megakaryocytes and lodgment in distal digits. At these sites, the megakaryocytes secrete various growth factors that finally result in the proliferation of fibroblasts.

PGE2 is significantly related to the pathogenesis of secondary HOA, which is shown by the increased levels of circulating PGE2 along with urinary excretion of PGE-M by the patients. The symptoms of HOA are also related to the VEGF, which is also derived and induced in hypoxic condition from platelets. VEGF helps in angiogenesis and osteoblastic differentiation.

It also induces vascular hyperplasia, edema and new bone formation which correlates with symptoms of HOA. HOA is also called Bamberger-Marie syndrome or Osteoarthropathia hypertrophicans.

### Conclusion

Clubbing is an important sign in the physical examination, which can lead to early detection of disease.

### Conflict of interest

None declared.

### References

1. Hippocrates. Prognostic. In: Jones WH. Hippocrates. 1<sup>st</sup> ed, Vol II. London: Loeb Classical Library, No. 148, William Heinemann Ltd; 1923. p. 7-55. Available from: <http://www.archive.org/details/hippocrates02hippuoft>.
2. Martinez-Lavin M. Exploring the cause of the most ancient clinical sign of medicine: Finger clubbing. *Semin Arthritis Rheum*. 2007 Jun;36(6):380-5.
3. Touraine G, Solente A, Golé L. Pachidermoperiostitis. *Presse Med* 1935;43:1820-4.
4. Altman RD, Tenenbaum J. Hypertrophic osteoarthropathy. In: Kelly WN, Harris ED, Ruddy S, editors. *Textbook of Rheumatology*. 5<sup>th</sup> ed. Philadelphia: WB Saunders Company; 1997:1514-20.
5. Yeung SC, Habra MA, Thosani SN. Lung cancer-induced paraneoplastic syndromes. *Curr Opin Pulm Med*. 2011 Jul;17(4):260-8.
6. Dickinson CJ, Martin JF. Megakaryocytes and platelet clumps as the cause of finger clubbing. *Lancet*. 1987 Dec 19;2(8573):1434-5.
7. Kozak KR, Milne GL, Morrow JD, et al. Hypertrophic osteoarthropathy pathogenesis: a case highlighting the potential role for cyclooxygenase-2-derived prostaglandin E2. *Nat Clin Pract Rheumatol*. 2006 Aug;2(8):452-6.
8. Johnson JC, Schmidt CR, Shrubsole MJ, et al. Urine PGE-M: A metabolite of prostaglandin E2 as a potential biomarker of advanced colorectal neoplasia. *Clin Gastroenterol Hepatol*. 2006 Nov;4(11):1358-65.
9. Atkinson S, Fox SB. Vascular endothelial growth factor (VEGF): A and platelet-derived growth factor (PDGF) play a central role in the pathogenesis of digital clubbing. *J Pathol*. 2004 Jun;203(2):721-8.
10. Armstrong DJ, McCausland EM, Wright GD. Hypertrophic pulmonary osteoarthropathy (HPOA) (Pierre Marie-Bamberger syndrome): Two cases presenting as acute inflammatory arthritis. Description and review of the literature. *Rheumatol*. 2007 Feb;27(4):399-402.
11. Deller A, Heuer B, Wiedeck H. Is myositis ossificans following ARDS a complication of prone-dependency or is it osteoarthropathia hypertrophicans (Bamberger-Marie syndrome)? *Intensive Care Med* 1998 Dec;24(12):1345-6.